

# SIERRA-SACRAMENTO VALLEY EMS AGENCY

## ALS PROTOCOL - MEDICAL EMERGENCY

**PEDIATRIC**  
REFERENCE NO. P-20

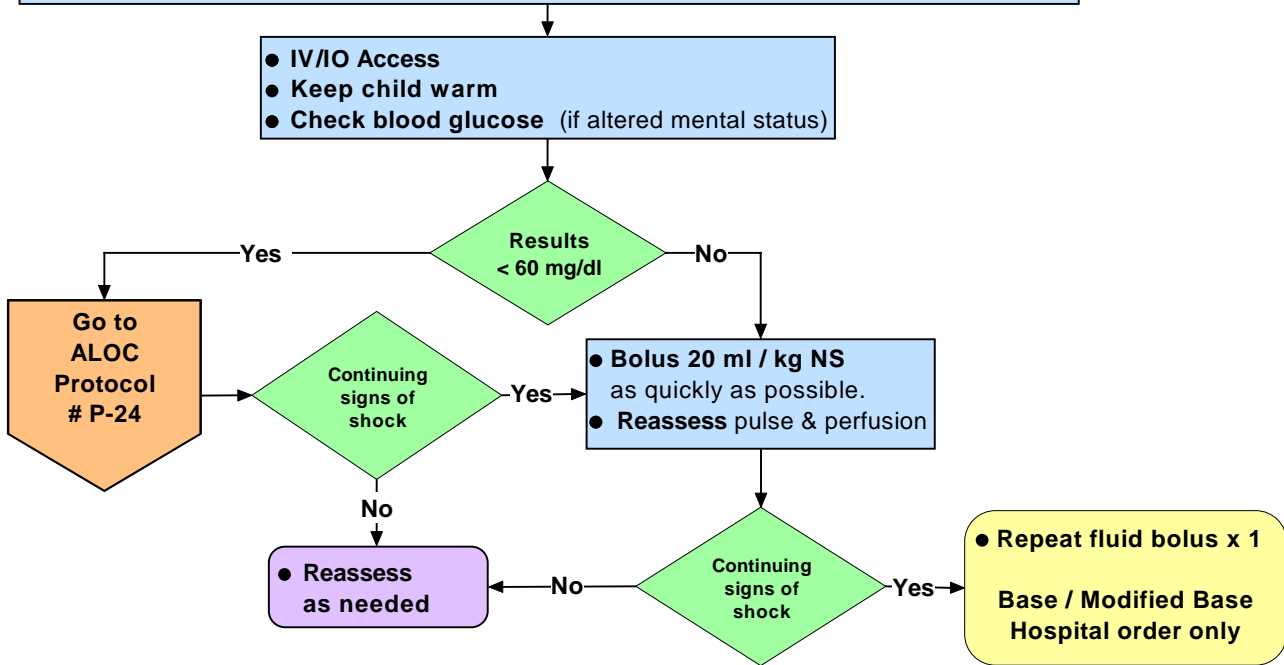
**SUBJECT: SHOCK**

- **Assess ABCs**
- **Note:** Shock in children may be subtle and difficult to recognize. Tachycardia may be the only sign noted. Hypotension is a late sign of shock. Determining B/P may be difficult and readings may be inaccurate in children under 3 years of age.
- **Obtain History**
  - ⇒ Onset and duration of symptoms
  - ⇒ Fluid loss (nausea, vomiting, diarrhea)
  - ⇒ Fever, infection, trauma, ingestion
  - ⇒ History of: allergic reaction, cardiac disease or rhythm disturbances

● **Important Signs to Watch For:**

COMPENSATED SHOCK	DECOMPENSATED SHOCK
<ul style="list-style-type: none"> <li>⇒ Tachycardia</li> <li>⇒ Cool extremities</li> <li>⇒ Capillary refill &gt; 2 seconds (despite warm ambient temperature)</li> <li>⇒ Weak peripheral pulses compared with central pulses</li> <li>⇒ Normal blood pressure</li> </ul>	<ul style="list-style-type: none"> <li>⇒ Hypotension and/or bradycardia (late findings)</li> <li>⇒ Decreased Mental Status</li> <li>⇒ Decreased urine output</li> <li>⇒ Metabolic acidosis</li> <li>⇒ Tachypnea</li> <li>⇒ Non-detectable distal pulses with weak central pulses</li> </ul>

- **ABCs** - O<sub>2</sub>, ventilation; suction as needed
- **Note:** Perform endotracheal intubation only if BVM ventilation is unsuccessful or impossible
- **Monitor**
- **Transport**



Effective Date: 02/01/07  
Next Review Date: 09/09  
Approved by:

Date last reviewed revised: 09/06  
Page 1 of 1

*William J. Koenig, MD*  
S-SV EMS Medical Director

*Leonard R. Inch*  
S-SV EMS Regional Executive Director