



**SIERRA SACRAMENTO VALLEY EMS AGENCY
TREATMENT PROTOCOL – MEDICAL EMERGENCY**

**PEDIATRIC
REFERENCE NO. P-20 (LALS)**

SUBJECT: SHOCK

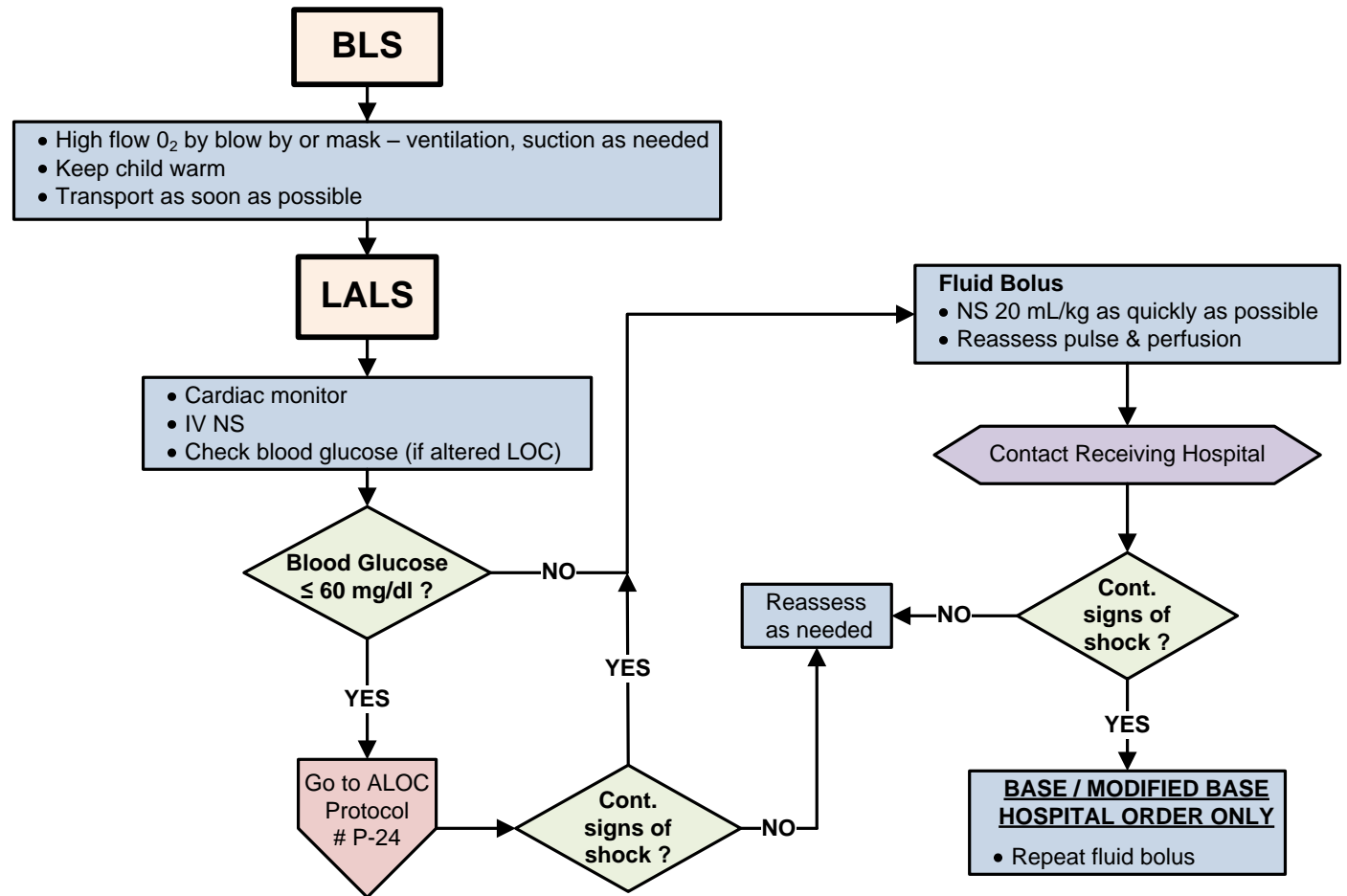
- Shock in children may be subtle and difficult to recognize. Tachycardia may be the only sign noted. Hypotension is a late sign of shock. Determining B/P may be difficult and readings may be inaccurate in children < 3 years of age
- Obtain History Including:
 - Onset and duration of symptoms
 - Fluid Loss (vomiting, diarrhea)
 - Fever, infection, trauma or ingestion
 - History of: allergic reaction, cardiac disease or rhythm disturbances
- Important signs to watch for:

COMPENSATED SHOCK

- Tachycardia
- Cool extremities
- Capillary refill time > 2 seconds (despite warm ambient temperature)
- Weak peripheral pulses compared with central pulses
- Normal blood pressure

DECOMPENSATED SHOCK

- Hypotension and / or bradycardia (late findings)
- Decreased mental status
- Decreased urine output
- Tachypnea
- Non-detectable distal pulses with weak central pulses



Effective Date: 07/01/2010
Next Review Date: 06/2012
Approved by:

Date last reviewed revised: 06/10
Page 1 of 1

SIGNATURE ON FILE
S-SV EMS Medical Director

SIGNATURE ON FILE
S-SV EMS Regional Executive Director